

# Endoscopic Endonasal Nasopharyngectomy in Selected Cancers

Paolo Castelnuovo, MD<sup>1</sup>, Piero Nicolai, MD<sup>2</sup>,  
Mario Turri-Zanoni, MD<sup>1</sup>, Paolo Battaglia, MD<sup>1</sup>,  
Andrea Bolzoni Villaret, MD<sup>2</sup>, Stefania Gallo, MD<sup>1</sup>,  
Maurizio Bignami, MD<sup>1</sup>, and Iacopo Dallan, MD<sup>1</sup>

Otolaryngology—  
Head and Neck Surgery  
149(3) 424–430  
© American Academy of  
Otolaryngology—Head and Neck  
Surgery Foundation 2013  
Reprints and permission:  
sagepub.com/journalsPermissions.nav  
DOI: 10.1177/0194599813493073  
http://otojournal.org



No sponsorships or competing interests have been disclosed for this article.

## Abstract

**Objective.** To describe the different surgical techniques for nasopharyngeal endoscopic resection (NER) and to support the efficacy of the endoscopic endonasal approach in the management of selected primary and locally recurrent nasopharyngeal tumors (NPTs).

**Study Design.** Case series with chart review.

**Setting.** Patients affected by NPTs who underwent NER from 1997 to 2011 at two Italian referral centers.

**Subjects and Methods.** NER was tailored to the NPT extension and classified as follows: type 1 NER, resection of the posterior nasopharyngeal wall; type 2 NER, resection superiorly extended to the sphenoid; type 3 NER, trans-pterygoid approach to the postero-lateral nasopharynx with removal of pterygoid plates and Eustachian tube, under control of parapharyngeal-petrous-cavernous segments of the internal carotid artery.

**Results.** Thirty-six consecutive patients with primary (9 cases) or locally recurrent (27 cases) NPTs were enrolled. The lesions were staged as follows: stage I, 16 (44.4%); stage II, 3 (8.4%); stage III, 15 (41.6%); and stage IVA, 2 (5.6%). Type 1 NER was performed in 6 cases, type 2 NER in 12, type 3 NER in 16, and bilateral-extended type 3 NER in 2. No perioperative mortality or major complications were observed. Postoperatively, 11 patients received intensity-modulated radiotherapy, with or without chemotherapy. Follow-up ranged from 2 to 173 months (mean: 38 months). Five years overall, disease-specific, and disease-free survivals were  $75.1\% \pm 9.13\%$ ,  $80.9\% \pm 7.79\%$ , and  $58.1\% \pm 14.8\%$ , respectively.

**Conclusion.** NER is a feasible and minimally invasive surgical approach for the management of selected primary and locally recurrent NPTs. Our preliminary outcomes are promising, with local control rates comparable to those of conventional procedures. Larger case series and longer follow-up are needed to validate the reproducibility and efficacy of the technique.

## Keywords

oncology, skull base, pharynx, nasal cavity, carcinoma

Received November 25, 2012; revised March 27, 2013; accepted May 17, 2013.

## Introduction

Radiotherapy (RT) associated or not with chemotherapy (CHT) is the gold standard of treatment for nasopharyngeal carcinoma (NPC).<sup>1</sup> Except for selected histotypes, surgery is mostly limited to tissue sampling or to salvaging selected patients with residual or persistent local or recurrent regional tumor. External approaches have been extensively described,<sup>2,3</sup> while only a few studies concerning endoscopic endonasal techniques have been reported.<sup>4,5</sup> The first experiences dealing with the endoscopic endonasal approaches were encouraging, showing adequate visualization of tumor margins with complete oncologic resection, thus avoiding facial scarring or deformity and preserving the neurologic and masticatory function.<sup>6,7</sup> At the present time, the major technical challenge encountered when accessing this area through the endonasal corridor still remains the restricted working space in proximity of critical neurovascular structures. Greater anatomical knowledge, refinement of imaging techniques, and the evolution of surgical expertise in endoscopic endonasal approaches have all contributed in the effort devoted to overshooting the present-day surgical limits.<sup>8</sup> In this study, we describe different surgical endoscopic endonasal approaches to the nasopharynx, depending on the local extension of the disease. Moreover, we evaluate the reproducibility, complications, and outcomes of endoscopic endonasal surgery in the management of

<sup>1</sup>Department of Otorhinolaryngology, University of Insubria, Varese, Italy

<sup>2</sup>Department of Otorhinolaryngology, University of Brescia, Brescia, Italy

This article was presented at the 2012 AAO-HNSF Annual Meeting & OTO EXPO; September 9–12, 2012; Washington, DC.

## Corresponding Author:

Mario Turri-Zanoni, MD, Department of Otorhinolaryngology, University of Insubria, Varese, Via Guicciardini 9, Varese, Italy.  
Email: tzmario@inwind.it

selected primary and locally recurrent nasopharyngeal tumours (NPTs).

## Methods

We performed a retrospective analysis of patients affected by primary and locally recurrent NPTs, treated with curative intent through an endoscopic endonasal approach at 2 Italian tertiary care centers, from January 1997 to December 2011. Approval was obtained from the Varese and Brescia Institutional Review Boards. All the patients gave their informed consent to participate in this survey. All the NPTs were staged according to the American Joint Committee on Cancer (AJCC) staging system, 7th edition.

Endoscopic examination and imaging studies such as computed tomography (CT) and magnetic resonance (MR) were used to evaluate the local extension of the tumor. Regional or distant dissemination of disease was preoperatively excluded by performing neck ultrasound and total body PET-CT scan. Moreover, an angio-CT scan (and/or intracranial angiography) was always obtained in order to clearly define anatomic variations of the parapharyngeal and paraclival course of the internal carotid artery (ICA). When the NPT was in relation with the parapharyngeal, petrous, or cavernous segment of the ICA, without encasement of the vessel but requiring an expanded endonasal resection, the possibility of intravascular stent placement was considered. The ICA stenting was helpful for improving the surgical management of the vessel, protecting it from iatrogenic injuries, and reducing postoperative risk of complication, especially regards the parapharyngeal segment of the ICA that requires consistency and stability among the muscular planes to be managed safely. The carotid stenting was performed under general anesthesia as a separate procedure, sometimes during diagnostic angiography. The Solitaire AB Neurovascular Remodelling Device (ev3 Inc, Plymouth, Minnesota) was the self-expanding stent employed. To reduce the risk of thromboembolic complications, a dual antiplatelet therapy was administrated for 30 days after stenting and then reduced to single-drug treatment.

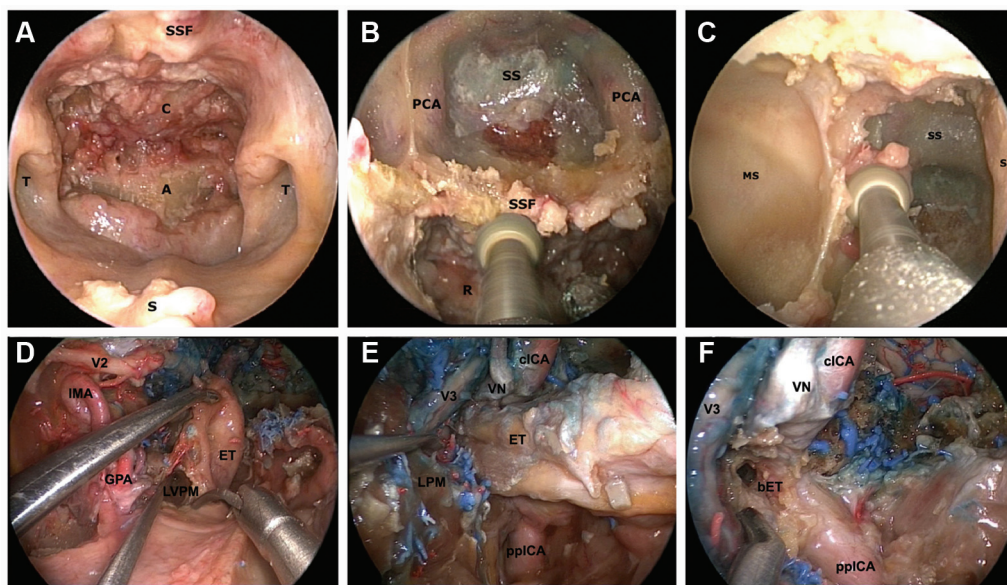
## Contraindications

Patients were considered unsuitable for nasopharyngeal endoscopic resection (NER) in the case of massive intracranial intradural involvement, orbital content invasion, and encasement of the ICA by the tumor.

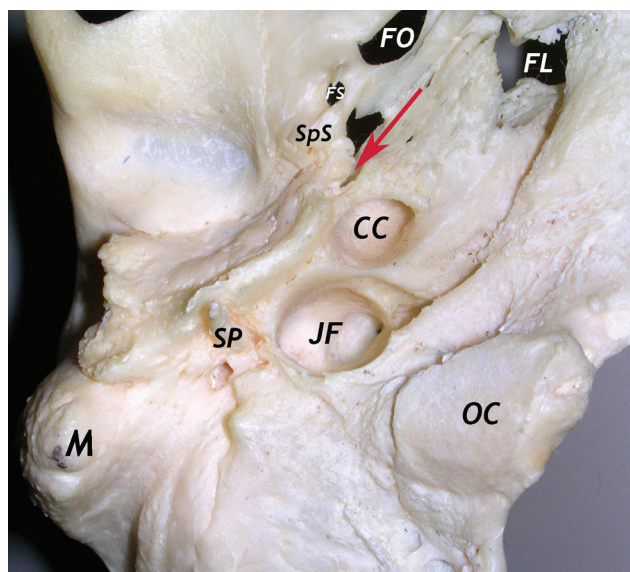
## Surgical Technique

Hypotensive general anesthesia was performed in all cases. A perioperative prophylactic antibiotic regimen included third-generation cephalosporin with cerebral spinal fluid penetration. The nasal cavities were packed prior to surgery with cottonoids soaked in 2% oxymetazoline, 1% oxybuprocaine and adrenaline (1/100.000) solution for 10 minutes, to reduce bleeding and improve transnasal access in terms of operative space. The extent of surgical resection was classified into 3 subtypes according to the extension of disease.<sup>7</sup> Type 1 NER started with the removal of the posterior

portion of the nasal septum. The resection was limited to the postero-superior nasopharyngeal wall, reaching the bony floor of the sphenoid sinus superiorly and the pharyngo-basilar/prevertebral fascia posteriorly. Type 2 NER was superiorly extended to include also the anterior wall and the floor of the sphenoid sinus. In this case, the sphenoid rostrum and the intersphenoidal septum were removed. Type 3 NER was extended laterally to include the lateral nasopharyngeal wall and the cartilaginous portion of the Eustachian tube. An ipsilateral endoscopic medial maxillectomy with the removal of the inferior turbinate, medial maxillary wall, and naso-lacrimal duct was extended as far as the pyriform aperture. In selected cases, a modified Denker approach was performed to enlarge the surgical corridor. The posterior wall of the antrum was drilled out to provide good exposure of the tumor. The sphenopalatine artery (SPA), the greater palatine artery, the vidian bundle, and the palato-vaginal artery were exposed, cauterized, and cut in order to mobilize laterally the soft tissues within the pterygo-palatine fossa. Only the septal branches of the SPA are spared when a naso-septal flap is needed for reconstruction; nevertheless, the other branches are resected for improving the storage of the flap in the antrum. Taking advantage of the transethmoid-ptyergoid approach with the drilling out of the medial and lateral pterygoid plates, the postero-lateral nasopharynx was removed together with the cartilaginous tube, the peritubaric muscles (levator and tensor veli palatine), and the upper portion of the pterygoid muscles. To perform these steps safely, it was mandatory to identify and have control of the parapharyngeal, petrous, and cavernous segments of the ICA. Medially, the vidian canal was a useful landmark for recognizing the junction between the intrapetrous and paraclival segments of the ICA. Once the lacerum segment of the ICA was identified, the bone of its horizontal petrous segment was carefully removed. Laterally, the cartilaginous portion of the Eustachian tube was resected as far as the bony tube, which was a critical landmark for recognizing the junction between the intrapetrous and parapharyngeal segments of the ICA (**Figure 1**). The musculo-tubal canal, the spine of the sphenoid bone with the sphenomandibular ligament, and the foramen spinosum (with the middle meningeal artery) were critical landmarks that were very useful to the surgeon as guides for identifying the carotid canal. From an anterior to posterior viewpoint, an anatomical sequence could be used to localize the carotid canal: foramen ovale, foramen spinosum, spine of the sphenoid bone, musculo-tubal canal, and carotid canal (**Figure 2**). In all the cases, the surgical margins were carefully examined with frozen section and the surgical procedure was continued until the tissue margins were clear of tumor or until further resection was impossible due to invasion of critical structures. A magnetic navigation image guidance system (Medtronic Navigation, Inc, Louisville, Colorado) was used intraoperatively for laterally extended tumors to recognize specific anatomical landmarks orienting the surgeon during the procedure. The angio-CT and MR images were processed with the fusion software of the navigation system to increase



**Figure 1.** Step-by-step endoscopic transnasal nasopharyngectomy. (A) Type 1 NER; (B) type 2 NER; (C) endoscopic medial maxillectomy; (D) surgical field after removal of pterygoid plates; (E) relationship between cartilaginous Eustachian tube, vidian nerve, and ICA; (F) relationship between bony Eustachian tube and ICA. Abbreviations: A, atlas; bET, bony Eustachian tube; C, clivus; clICA, cavernous ICA; ET, Eustachian tube; GPA, greater palatine artery; ICA, internal carotid artery; IMA, internal maxillary artery; LPM, lateral pterygoid muscle; LVPM, levator veli palatine muscle; MS, maxillary sinus; NER, nasopharyngeal endoscopic resection; PCA, paracaval carotid artery; pplICA, parapharyngeal ICA; S, septum; SS sphenoidal sinus; SSF, sphenoidal sinus floor; T, torus tubarius; V2, second branch of the trigeminal nerve; V3, third branch of the trigeminal nerve; VN, vidian nerve.



**Figure 2.** Osteologic representation of the sequence of anatomical structures useful for safely localizing the carotid canal intraoperatively: foramen ovale (FO), foramen spinosum (FS), spine of the sphenoid bone (spS), musculo-tubal canal (red arrow), and finally, the carotid canal (CC). Abbreviations: FL, foramen lacerum; JF, jugular foramen; M, mastoid process; OC, occipital condyle; SP, styloid process.

the safety of the surgery. An acoustic Doppler ultrasound probe was also employed for the identification of critical vessels. The surgical wound was left free to heal by secondary

intention in cases of types 1 and 2 NER; when an expanded resection with exposure of the ICA and/or skull base was performed (selected cases of type 3 NER), the surgical field was resurfaced using a pedicled flap (Hadad-Bassagaisteguy flap in most of the cases) harvested at the beginning of surgery and temporarily stored in the antrum during the demolition phase. When the tumor was bilaterally extended involving the nasal septum, for defects too large to be covered, or in the case of radiation-induced degeneration of the nasal mucosa, a temporo-parietal fascia flap (TPFF) was harvested and inserted into the nose through a trans-ptyergoid tunnel.<sup>9,10</sup> Otherwise, the field was covered by fascial grafts. Nasal packing was removed 24 to 48 hours after the surgical procedure.

### Statistical Analysis

All data were collected and processed with a commercially available computer software package (SPSS for Windows, Version 19, 2010, SPSS, Inc, Chicago, Illinois). The estimated distribution of the overall survival (OS), disease-specific survival (DSS), and disease-free survival (DFS) was calculated using the Kaplan–Meier method and the log-rank test. Univariate and multivariate analyses of survival were carried out using an explorative Cox-proportional hazards model, considering *P*-values below .05 as significant.

### Results

According to the selection criteria adopted, 36 consecutive patients with primary (9 cases) or locally recurrent (27 cases) NPTs were enrolled in this survey. Among the group



**Table 1.** Outcomes and follow-up status of primary and locally recurrent nasopharyngeal tumors included in this case series, according to the T classification at presentation.

Presentation	T Classification	Follow-Up	
		Status	Months
Primary	5, T1	4 NED, 1 DOD	12-53 (mean, 31)
	1, T2a	1 DOD	173
	2, T3	1 NED, 1 AWD	32, 41
	1, T4	1 AWD	119
Recurrent	12, rT1	10 NED, 1 DOD, 1 DOC	5-137 (mean, 37)
	1, rT2a	1 NED	59
	13, rT3	8 NED, 2 AWD, 3 DOD	2-85 (mean, 26)
	1, rT4	1 AWD	3

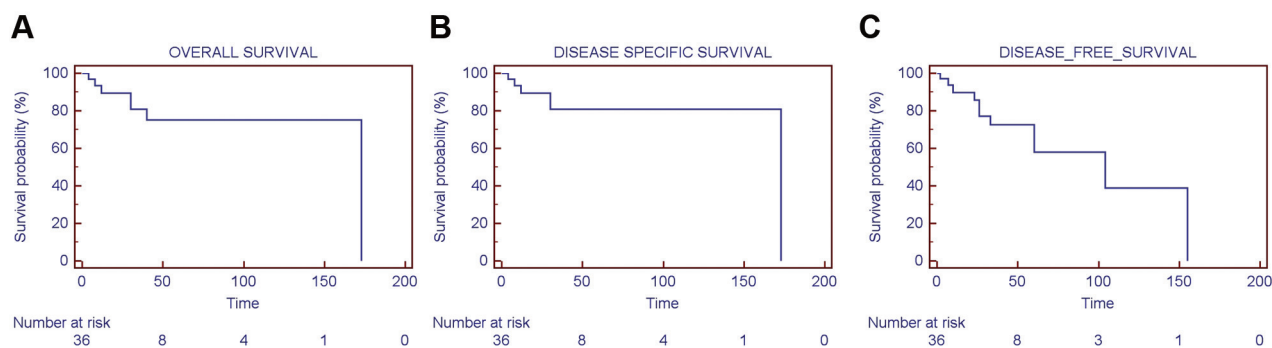
Abbreviations: AWD, alive with disease; DOC, dead of other causes; DOD, dead of disease; NED, no evidence of disease.

with recurrent disease, 20 patients had been treated previously with chemoradiation therapy, associated with radical neck dissection in 4 cases; 6 patients received radiotherapy alone; and 1 patient chemotherapy alone. The lesions were staged as follows: stage I, 16 (44.4%) patients; stage II, 3 (8.4%) patients; stage III, 15 (41.6%) patients; and stage IVA, 2 (5.6%) patients. The histotypes encountered were the recurrence of undifferentiated carcinoma of nasopharyngeal type (UCNT) (WHO type III) (19/36, 53%), squamous cell carcinoma (WHO, type I-II) (4/36, 11%), adenoid cystic carcinoma (4/36, 11%), adenocarcinoma (4/36, 11%), plasmocytoma (2/36, 5.5%), sarcoma (2/36, 5.5%), and melanoma (1/36, 3%). All surgeries were performed through an endoscopic endonasal approach with curative intent. Only 1 patient with recurrent UCNT presented with cervical metastases (staged rT1N1M0), thus requiring a neck dissection as part of the surgical treatment. Type 1 NER was performed in 6 cases, type 2 NER in 12 cases, type 3 NER in 18 cases (monolateral in 16 cases and bilateral-extended in 2 cases). Preoperative ICA stenting was performed in 2 cases of type 3 NER because of the close relationship between the tumor and the vessel (lacerum segment in one case, parapharyngeal portion in the other one). In our limited experience, this procedure obtained good results in terms of ICA preservation and surgical ability to maneuver instruments and to dissect. Moreover, 16 of the 18 extended nasopharyngectomies (type 3 NER) had been performed in recent years (after 2006), and the surgical wound was covered with either a pedicled nasoseptal flap or a TPFF, tailored to the extension of the tumor and the resulting defect, to speed the healing process and to decrease the risk of complications. In our series, we did not have to convert the endoscopic approach to a traditional open procedure in any of the patients. The margin status, assessed with intraoperative frozen section and confirmed with the definitive histopathological results, was negative in 92% (33/36) of the cases. In 3 patients with recurrence of UCNT, the radiation-induced scars and necrosis of the tissues had made the tumor incompatible with safe radical surgical clearance, whether endoscopic or open, unless at the cost of sacrificing the ICA. No

perioperative mortality or major complications were observed in our series. Minor complications, alone or combined, occurred in 9 of 36 patients: occipital headache (2 cases of type 1 NER, 1 case of type 2 NER, and 5 cases of type 3 NER), numbness of the hard palate ipsilateral to the surgical resection (2 cases of type 3 NER), persistent glue ear with disabling conductive hearing loss (4 cases of type 3 NER), and temporary postoperative masticatory impairment (3 cases of type 3 NER). However, no patients reported either masticatory deficits or impaired swallowing in a long-term follow-up. Mean hospitalization stay was 7.2 days (range, 2-14) and all patients were discharged with nasal irrigation with saline solution and systemic antibiotic therapy. Postoperative adjuvant treatments were administered to 11 of 36 (30.5%) patients, including 7 of 9 primary NPTs who received intensity-modulated radiation therapy and 4 of 27 recurrent NPTs (who received chemotherapy alone in 2 cases and chemoradiation therapy in 2 cases). Follow-up ranged from 2 to 173 months (mean: 38 months; median: 32.5 months). At the time of the last follow-up, 24 (67%) patients were free of disease (but only 5 of them had actually reached the minimum 5 years of follow-up), 5 (13.7%) were alive with disease, 1 (2.7%) had died of other causes (acute respiratory failure), and 6 (16.6%) had died of the disease (**Table 1**). Considering the entire study population, the 5 years overall, disease-specific, and disease-free survivals were 75.1%  $\pm$  9.13%, 80.9%  $\pm$  7.79%, and 58.1%  $\pm$  14.8%, respectively (**Figure 3**). Remarkably, the survival rates analyzed in the group of recurrent NPTs were poorer, with the 5 years overall, disease-specific, and disease-free survivals of 72.5%  $\pm$  10.8%, 79.8%  $\pm$  9.1%, and 55.6%  $\pm$  17.8%, respectively.

## Discussion

The management of patients with recurrent nasopharyngeal cancers is a difficult undertaking with poor prognosis and recurrence rates ranging from 19% to 56%, depending on the initial stages of disease.<sup>11,12</sup> Surgery could be one option of treatment for this subset of patients, among a variety of modern re-irradiation protocols including stereotactic, brachytherapy, proton, or intensity modulated therapy.<sup>13,14</sup>



**Figure 3.** Kaplan–Meier survival rates of the population enrolled in the study. (A) 5 years overall survival of  $75.1\% \pm 9.13\%$ ; (B) 5 years disease-specific survival of  $80.9\% \pm 7.79\%$ ; (C) 5 years disease-free survival of  $58.1\% \pm 14.8\%$ .

External surgical approaches have been described as a possible treatment in cases of recurrent NPTs, but entailing non-negligible morbidity for the patient. In the past few years, endoscopic endonasal procedures have been proposed as an alternative to traditional external approaches, not only for the management of recurrent nasopharyngeal carcinoma but also as a method of primary treatment for selected cancers, with glandular or mesenchymal differentiation, which are considered not suitable for RT and/or CHT. NER allows reaching the nasopharynx where the cancer is located by passing through the nasal fossae without the need for the skin incisions and maxillary osteotomies that are frequently associated with persistent or transitory complications such as chronic dacryocystitis, cheek paraesthesia, and temporary diplopia. Endoscopes also provide magnified images and the possibility to explore around corners, thanks to their angled view, so that the tumor margins can be well identified and controlled. The anatomic limits for safe NER are the dura of the posterior cranial fossa posteriorly and the ICA laterally, requiring a careful preoperative study of these structures to avoid major neurovascular complications.<sup>15</sup> To expose and preserve these critical structures intraoperatively, we perform a posterior septectomy associated with a large medial maxillectomy (and/or modified Denker approach) in order to remove the posterior wall of the antrum, to mobilize the soft tissue of the pterygopalatine fossa, and then to remove the pterygoid processes and cartilaginous portion of the Eustachian tube.<sup>16</sup> In this manner, we obtain enough surgical space to perform a careful and precise bimanual dissection according to the “two-nostrils four-hands technique.”<sup>17</sup> In addition, this approach allows control of the parapharyngeal, petrous, and cavernous segments of the ICA, which is a critical step for safely and completely resecting laterally extended nasopharyngeal cancers.<sup>6</sup> Anatomically speaking, we stress the importance of working at the level of the skull base where there are sound bony landmarks that can guide to the identification of the upper parapharyngeal portion of the ICA. On the contrary, no landmark can be considered safe within the parapharyngeal space because of the possibility of looping or kinking of the vessel. In fact, also the styloid muscles, which cover the major vessels (ICA and internal jugular vein) laterally at skull

base level and in the upper parapharyngeal space, more inferiorly can be overtaken anteriorly by the ICA, thus posing at extreme risk an endoscopic endonasal surgery based on their role.<sup>18</sup> Once the carotid canal has been exposed, the artery is identified and it can be followed under visual control within the parapharyngeal space. Ultrasound tools should be used in this kind of procedure to increase the ability to localize the vessel. Furthermore, the ICA stenting is a pre-operative procedure that must be discussed with selected patients affected by laterally extended tumors; its aim is to protect the vessel from iatrogenic injuries and help the surgeon in the identification and dissection of the lesion intraoperatively. On the other hand, the patient should be informed that this intravascular procedure requires long-term antiplatelet therapy. However, previous experiences with ICA stenting for different surgical approaches confirmed our impression that neither major complications nor significant patient morbidity occur with this procedure.<sup>19–21</sup> When the ICA and posterior/middle skull base were dissected and exposed, the surgical field was resurfaced using a pedicled nasoseptal flap or TPF to promote the healing and to protect the neurovascular structures exposed, especially in the cases requiring adjuvant radiotherapy.

Our study was a preliminary evaluation of the results concerning the endoscopic management of primitive or locally recurrent nasopharyngeal tumours, focusing on surgical techniques, perioperative complications, and local control of the disease. The actuarial overall survival rate in our series was 75%, decreasing to 58% when considering the disease-free survival rate, with a mean follow-up of 38 months (median: 32.5 months). Unfortunately, a significant statistical evaluation is not possible at the time of writing, on account of the small size of the patient cohort, the heterogeneous group of histotypes, and the limited follow-up. However, our survival rates were similar to the results of the other endoscopic endonasal experiences and they were comparable also with the outcomes after conventional open surgery procedures, emphasizing the aggressive biological behavior of malignant nasopharyngeal tumours, regardless of the surgical approach. Nevertheless, our data could support the feasibility and good tolerability of the endoscopic endonasal approaches in selected nasopharyngeal cancers. It is essential to remember that adequate patient

selection for NER is the critical point for avoiding major neurovascular complications, persistence of tumor, or having to convert to an open approach. Encasement of cavernous, petrous, or parapharyngeal segments of the ICA and massive intracranial extension toward the middle or posterior cranial fossa still remain absolute contraindications to an endoscopic endonasal resection with curative intent. Moreover, we emphasize that its indications and use are limited not only by the comorbidities of patient and the extent of disease, but also by the skill of the surgeon and by the availability of dedicated surgical instruments and intraoperative devices.

In conclusion, endoscopic endonasal nasopharyngectomy seems to be a feasible and minimally invasive surgical approach for managing selected primary and locally recurrent NPTs. Larger case series and longer follow-up are needed to validate the reproducibility and the outcomes of this technique. A future challenge regarding minimally invasive techniques for accessing the nasopharynx could be the development of robotic-assisted surgery, alone or combined with the transnasal endoscopic approaches.<sup>22</sup> The combined and blended solution, pioneered by the Ohio group, could probably overcome the limits of current technologies.<sup>23</sup> Taking advantage of the transoral corridor, the whole nasopharynx could be exposed with complete visualization of the ICA and the Eustachian tube bilaterally.<sup>24</sup> However, the 3-dimensional perspective and the considerable maneuverability of the surgical instruments have to be balanced with the need for a palatal incision that still remains the main disadvantage.<sup>25</sup>

## Author Contributions

**Paolo Castelnuovo**, revised the manuscript critically for important intellectual content, final approval of the version to be published; **Piero Nicolai**, revised the manuscript critically for important intellectual content, final approval of the version to be published; **Mario Turri-Zanoni**, conception and design of the study, acquisition of data, final approval of the version to be published; **Paolo Battaglia**, analysis and interpretation of data, final approval of the version to be published; **Andrea Bolzoni Villaret**, conception and design of the study, acquisition of data, final approval of the version to be published; **Stefania Gallo**, contribution on drafting the article, final approval of the version to be published; **Maurizio Bignami**, analysis and interpretation of data, final approval of the version to be published; **Iacopo Dallan**, revised the manuscript critically for important intellectual content, final approval of the version to be published.

## Disclosures

**Competing interests:** None.

**Sponsorships:** None.

**Funding source:** None.

## References

- Chen MK, Lai JC, Chang CC, et al. Minimally invasive endoscopic nasopharyngectomy in the treatment of recurrent T1-2a nasopharyngeal carcinoma. *Laryngoscope*. 2007;117:894-896.
- Wei WL. Salvage surgery for recurrent primary nasopharyngeal carcinoma. *Crit Rev Oncol Hematol*. 2000;33:91-98.
- Fisch U. The infratemporal fossa approach for nasopharyngeal tumors. *Laryngoscope*. 1983;93:36-44.
- Yoshizaki T, Wakisaka N, Muro S, et al. Endoscopic nasopharyngectomy for patients with recurrent nasopharyngeal carcinoma at the primary site. *Laryngoscope*. 2005;115:1517-1519.
- Chen MY, Wen WP, Guo X, et al. Endoscopic nasopharyngectomy for locally recurrent nasopharyngeal carcinoma. *Laryngoscope*. 2009;119:516-522.
- Al-Sheibani S, Zanation AM, Carrau RL, et al. Endoscopic endonasal transpterygoid nasopharyngectomy. *Laryngoscope*. 2011;121:2081-2089.
- Castelnuovo P, Dallan I, Bignami M, et al. Nasopharyngeal endoscopic resection in the management of selected malignancies: ten-year experience. *Rhinology*. 2010;48:84-89.
- Ong YK, Solares CA, Lee S, et al. Endoscopic nasopharyngectomy and its role in managing locally recurrent nasopharyngeal carcinoma. *Otolaryngol Clin North Am*. 2011;44:1141-1154.
- Chen MY, Wang SL, Zhu YL, et al. Use of a posterior pedicle nasal septum and floor mucoperiosteum flap to resurface the nasopharynx after endoscopic nasopharyngectomy for recurrent nasopharyngeal carcinoma. *Head Neck*. 2012;34:1383-1388.
- Hadad G, Bassagasteguy L, Carrau RL, et al. A novel reconstructive technique after endoscopic expanded endonasal approaches: vascular pedicle nasoseptal flap. *Laryngoscope*. 2006;116:1882-1886.
- Sanguineti G, Geara FB, Garden AS. Carcinoma of the nasopharynx treated by radiotherapy alone: determinants of local and regional control. *Int J Radiat Oncol Biol Phys*. 1997;37:985-996.
- Sutton JB, Green JP, Meyer JL, et al. Nasopharyngeal carcinoma: a study examining Asian patients treated in the United States. *Am J Clin Oncol*. 1995;18:337-342.
- Roeder F, Zwicker F, Saleh-Ebrahimi L, et al. Intensity modulated or fractionated stereotactic reirradiation in patients with recurrent nasopharyngeal cancer. *Radiat Oncol*. 2011;6:22.
- Koutcher L, Lee N, Zelefsky M, et al. Reirradiation of locally recurrent nasopharynx cancer with external beam radiotherapy with or without brachytherapy. *Int J Radiat Oncol Biol Phys*. 2010;76:130-137.
- Chan JY, Chow VL, Tsang R, et al. Nasopharyngectomy for locally advanced recurrent nasopharyngeal carcinoma: exploring the limits. *Head Neck*. 2012;34:923-928.
- Hosseini SM, McLaughlin N, Carrau RL, et al. Endoscopic transpterygoid nasopharyngectomy: Correlation of surgical anatomy with multiplanar CT. *Head Neck*. 2013; 35:704-714.
- Castelnuovo P, Pistochini A, Locatelli D. Different surgical approaches to the sellar region: focusing on the "two nostrils four hands technique." *Rhinology*. 2006;44:2-7.
- Castelnuovo P, Dallan I, Tschabitscher M. *Surgical Anatomy of the Internal Carotid Artery: An Atlas for Skull Base Surgeons*. Berlin, Germany: Springer-Verlag GmbH; 2013.
- Konishi M, Piazza P, Shin SH, Sivalingam S, Sanna M. The use of internal carotid artery stenting in management of bilateral carotid body tumors. *Eur Arch Otorhinolaryngol*. 2011; 268:1535-1539.
- Sanna M, Piazza P, De Donato G, Menozzi R, Falcioni M. Combined endovascular-surgical management of the internal

- carotid artery in complex tympanojugular paragangliomas. *Skull Base*. 2009;19:26-42.
21. Sanna M, Khrais T, Menozi R, Piazza P. Surgical removal of jugular paragangliomas after stenting of the intratemporal internal carotid artery: a preliminary report. *Laryngoscope*. 2006;116:742-746.
22. Dallan I, Castelnovo P, Montevercchi F, et al. Combined transoral transnasal robotic-assisted nasopharyngectomy: a cadaveric feasibility study. *Eur Arch Otorhinolaryngol*. 2012; 269:235-239.
23. Carrau RL, Prevedello DM, de Lara D, Durmus K, Ozer E. Combined transoral robotic surgery and endoscopic endonasal approach for the resection of extensive malignancies of the skull base [published online March 6, 2013]. *Head Neck*. Doi: 10.1002/hed.23238.
24. Wei WI, Ho WK. Transoral robotic resection of recurrent nasopharyngeal carcinoma. *Laryngoscope*. 2010;120:2011-2014.
25. Yin Tsang RK, Ho WK, Wei WI. Combined transnasal endoscopic and transoral robotic resection of recurrent nasopharyngeal carcinoma. *Head Neck*. 2012;34:1190-1193.